

Gonads tissue changes of *Chalcalburnus mossulensis*(Heckel, 1843) infected by *Ligula intestinalis* (cestoda)

Parsa Khanghah, A.¹; Mojazi Amiri, B.²; Sharifpour, I.³; Jalali Jafari, B.^{1†};
Motalebi, A. A.³

Received: January 2010

Accepted: April 2010

Abstract

Chalcalburnus mossulensis from the *cyprinidae* family is one of the indigenous fish in Gheslgh Lake of Kordestan, Iran. *Ligula intestinalis* is one of the infective parasites among various species of fish and causes gonads atrophy. In this study, after detection of species and age of samples, the effects of this parasite on gonads tissues and sexual maturation of *Chalcalburnus mossulensis* were investigated. By seasonal sampling 144 samples were collected. After investigating gonad tissue samples, it was clear that, there is a significant difference between the means of male and female gonads maturation rate in infected and non infected samples ($p < 0.05$). Infection by *Ligula intestinalis* can be the reason for lack of gonads maturation. In addition, the abnormal degenerative changes like, absorption follicle, hemorrhage and infiltration of inflammation cells in ovary tissues of infected fish were seen. In testicle tissue, dispersed hemorrhage, atrophy and MMC (melano-macrophage center) were seen as pathological signs. So the spread of this parasite in different water sources is important as the point the maintenance of native species and cultivated fish.

Keywords: *Chalcalburnus mossulensis*, *Ligula intestinalis*, Gonads, Histopathology

1-Department of Health and Aquatic Diseases, Science and Research Branch, Islamic Azad University, P.O.Box:19585-181 Tehran, Iran.

2-Dept. of Fisheries and Environmental Sciences, Faculty of Natural Resources, University of Tehran, P.O.Box:31585-4314 Karaj, Iran

3- Iranian Fisheries Research Organization, P.O.Box:14155-6116, Tehran, Iran.

*Corresponding author's email: a.parsa@iausdj.ac.ir

Introduction

The Geshlagh Dam Lake, 12 kilometers away from the north of Sanandaj, with 38° North width and 30° East length is located on Geshlagh River (Najafi, 1990) and belongs to the ecological area of Mesopotamia (Jalali, 1998). *Chalcalburnus mossulensis* is one of the native fish in this region, which lives in Geshlagh River and its dam (Adeli, 2001; Kaivani, 2005). This fish, with a long mandible and body, belongs to the *Ciprinidae* family and lives in fresh water and brackish water (Sattari et al., 2004). Considering the fact that the multi-host parasitological diseases are seen among the wild fish and open areas, infection by *Ligula intestinalis* parasite in this lake is not impossible and some cases of infection have been reported (Eslami, 1997; Jalali, 1998; Jalali and Barzegar, 2006). The matured parasite is in the hindgut of the intestine of the fish-eating birds and after death, the eggs are released in the water, then the free coracidiums will be swallowed by the host-medium crustaceans. The host-medium crustaceans are then eaten by the fish and the parasite plerocercoids drill the fish intestine septum and enter the abdominal cavity of the fish. The number of plerocercoids in the abdominal cavity can also be reached 13 (Sharif Rohani, 1995; Jalali, 1998; Razmi, 2000; Mokhayer, 2002). Until now, *Ligula intestinalis* and *Digrama interrupta* have been reported only in the *cyprinidae* family. The difference between these species is the presence of a pair of female sexual systems in each proglotid of *Ligula* and two pairs of female sexual system in each proglotid of *Digrama*, which can be noticed by unequipped eyes. During the growth process, this parasite damages the

fish gonads in two ways: first, physical damage caused by parasites pressure onto viscera and second, infusing chemicals which affected the brain, hypophyses and gonad axis, which resulted in malfunction of the mentioned axis and inhibited LH hormone infusion that finally lead to immature gonads and immaturity (Choudhury and Dick, 1995; Jalali et al., 2008). Infection in Iran has had an extending spread and has been seen in the three regions of the country's ecology (Jalali, 1998). There are numerous reports on Ligulosis outbreaks in fresh water fish. The percentage of Ligulosis infection reported in silver carps in Hamoon marsh, was so high that it reached to 100% in summer (Sharif Rohani, 1995) also Ligulosis reported in Satarkhan Dam's fish (Mortazavi, 2004). According to the previous researches on Ligulosis outbreaks in Zerivar Lake of Iran, the maximum rate of infection is seen in autumn (28.91%) which has been mostly caused by 13 species of parasites (about 30.7 % of its weight) (Jalali et al., 2008). According to studies, 31 out of 47 fish species of *Cyprinidae*, could be the second intermediate host of *Ligula* (Dubinana, 1980). In the parasitological studies in Zerivar Lake the ligulosis outbreak was reported 15%, 60%, 15%, and 2% in summer, fall, winter and spring respectively (Jalali and Barzegar, 2006). During growth process in abdominal cavity this parasite causes malfunction in the maturation of gonads, which is called parasitic sterility that leads to fish reduction (Dubinana, 1980; Roberts, 2001). Various researches have studied the effects of this parasite on the rate of fish

reduction and have shown its negative effects on the growth process and reduction of the fish weight that similar to over ripening gonads (Gussev, 1985; Akmirza, 2004; Ergonul, 2005; Itindag, 2005; Bahre Kazemi et al., 2009).The study of gonads tissue in teleostei fish can also give sufficient information about sex , sexual maturation and the reproduction process (Eagderi, 2002).In addition, the study of gonads tissues changes during different seasons of the year and the time of reproduction is important in identifying reproduction disorders, especially in the spawning season. The aim of this research is to identify the effect of this parasite on gonads tissues of male and female fish and its effects on sexual maturity process of the fish during different seasons, that can guide supporting actions in fish stocks' preservation and reduction of their mortality, and has positive effect with generalization to other water resources and fish species regarding better production of economical fish.

Materials and methods

Since March 2007 to March 2008, in the second half of the second months of each season, sampling was done with small seine nets (0.5 cm) in the southern coast of Gheshlagh Dam, the samples were delivered lively to the laboratory of Veterinary Faculty of Azad University of Sanandaj and biometrical parameters and fish identification were evaluated (Saadati; 1977; Abdoli, 1999; Raissy et al., 2010).Thereafter the fish were killed by head trauma and the scale sample was taken off from the area between the pectoral fin and upper lateral line and washed in xylene and glycerol in order to

purify it, and then it was studied by a light-microscope (Adeli, 2001).The fish of the same age were autopsied separately and in the infected cases, sampling was done from the anterior part of gonads with 0.5×0.5 cm dimensions, then in order to gain tissue cross section they were added to buffered formalin 10%.The plerocercoids were also added to buffered formalin 10% and stained with Karmen. While *Ligula's* reproduction system is the same as a fissure in its ventral surface, it can be distinguished by unequipped eyes from its analogous *Digrama* parasite (Jalali et al., 2008).Simultaneously, the same aged noninfectious fish were autopsied and their gonads were sampled in the same way so that they could be compared in the next stages. The mentioned procedure was accomplished in all seasons.1000 fish were caught and after biometry, fish identification, age and infected status determination, 144 samples of them were picked out. In order to use a uniform method to study all fish, only the fish with plerocercoids higher than 1 gram weight in their abdominal cavity were selected. Then, using a rotary microtome, the tissue section of $6\mu\text{m}$ thickness was taken from the gonads samples and stained by Hematoxylin- eosin method (Pousti and Adibmoradi, 2003). By using light-microscope, fish sex with ovary and testicle maturation stages were distinguished (Eagderi, 2002).Then, the pathological damages of gonads were studied and the results were recorded. The obtained data were analyzed by the ANOVA test using the statistical software of SAS (version 9.0).The homogeneity of the statistical mean groups were studied by Bartlett test of this software and then the

relation between maturation stages of gonads of the non-infected and infected fish was determined (Soltani, 1998; Navabpoor, 2000).

Results

In this research, it was clear that in all samples that were taken in one year, the mean of gonad maturation stages (stage1 to stage6) in infected fish (2.57 ± 0.71), compared to the non-infected ones (3.89 ± 1.71) have a delay, especially in the spawning season and there has been a meaningful relationship among the gonads maturation stages of infected and non-infected male and female fish ($p < 0.05$).

The gonads maturation stages and

the comparison of their status in infectious and noninfectious fish in different seasons are as follow:

Spring:

The samples that were taken in spring, showed immaturity in most of the gonads in the infected male fish and only primary and secondary spermatogonium could be seen in them (Fig. 1). The immaturity of follicles could also be seen on the ovary tissue of the infected female fish (Fig. 2), while this could not be seen in noninfectious ones. In the gonads of non-infected fish, spermatozoid and matured follicles could be seen respectively, which is normal in the spawning season (Fig. 3, 4).

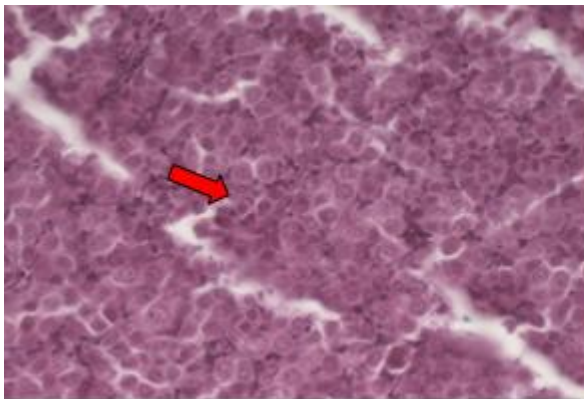


Figure 1: Testicle tissue of infected fishes Spermatogonium - H&E, X 400

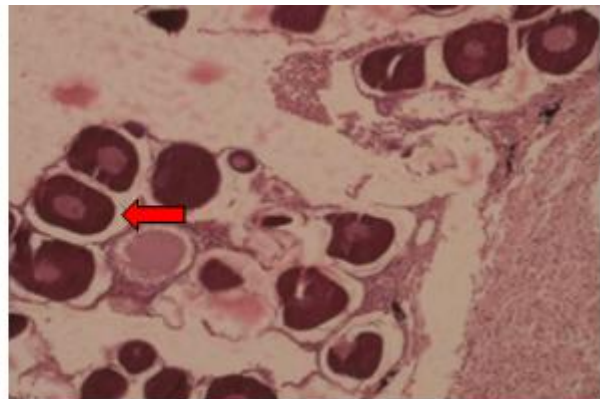


Figure 2: Ovary tissue of infected fishes-immatureFollicle - H&E, X 400

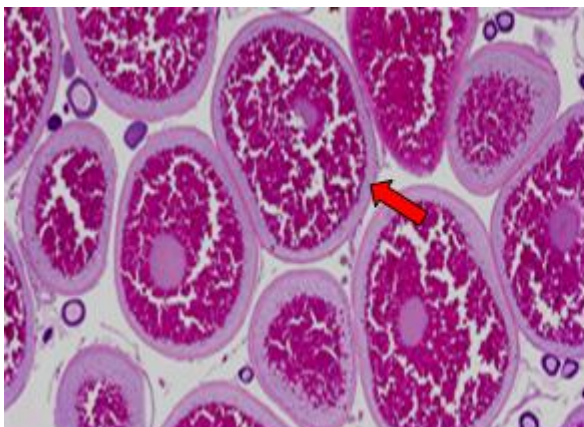


Figure 3: Ovary tissue of non - infected fishes matured follicle - H&E, X 400

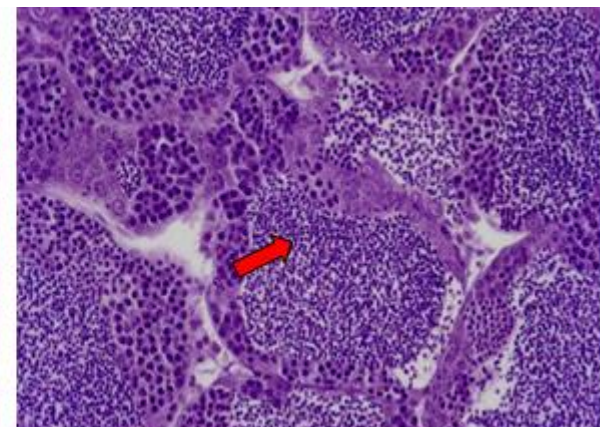


Figure 4: Testicle tissue of non - infected fishes spermatozoid - H&E, X 400

Summer:

Although the spawning of fish was terminating in this season and the gonads were returning to their inactive stage, the immaturity of follicles and atrophy in the ovary tissue were clear in infected female fish (Fig. 5).

In infected male fish, secondary

spermatocytes and spermatozoid could not be seen, and atrophy was clear in testicle tissues (Fig. 6). In comparison with infected fish, in non infected ones that were caught in this season, matured follicles and secondary spermatocytes in gonads could be seen (Fig. 7, 8).

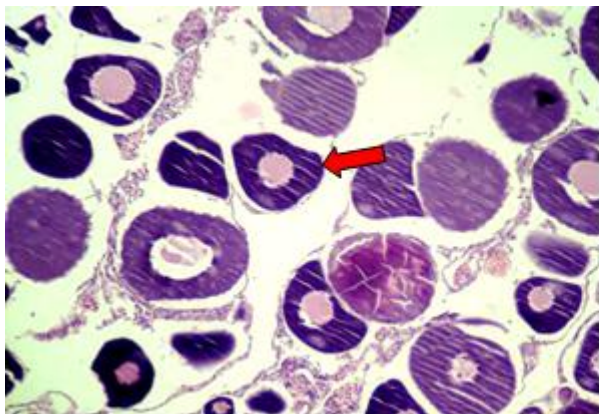


Figure 5: Ovary tissue of infected fishes immature follicle - H&E, X 400

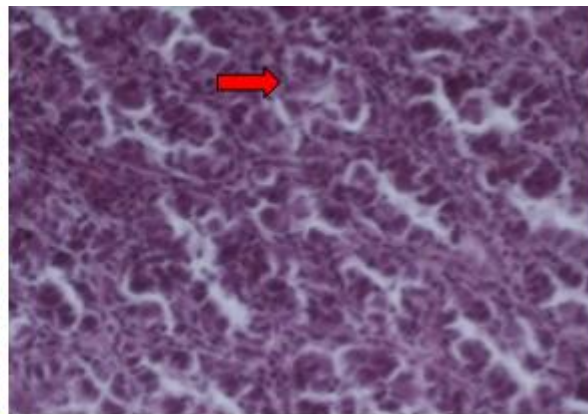


Figure 6: Testicle tissue of infected fishes spermatogonium - H&E, X 400

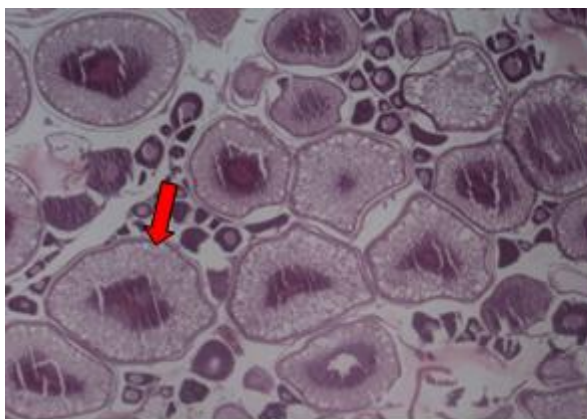


Figure 7: Ovary tissue of non - infected fishes matured follicle - H&E, X 400

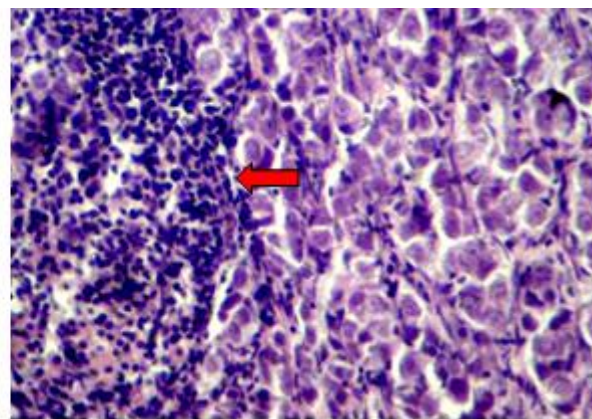


Figure 8: Testicle tissue of non - infected fishes secondary spermatocytes - H&E, X 400

Fall:

In this season, considering the entry of the gonads into the stage after ovulation and their inactive phase, distinguishing the noninfectious and infectious fish gonads tissues would be more difficult because of the resemblance between sexual cells in the first stage of gonads maturation, but non infected matured gonads (that have

produced ovum) from infected ones (that have not entered their maturation phase and only have prenucleolar stage follicles), by follicles coverage, non-released ovum and different growth stage oocytes (Fig. 9). In the testicle tissue, observing the secondary spermatocyte cells that have nucleus with diffuse chromosomes and without having nucleolus, could be the

reason for the gonads complete maturation and spermatozoid production by them, but this case could not be seen in the infected

fish's gonads and only the spermatogonium cells and primary spermatocyte cells were seen (Fig. 10).

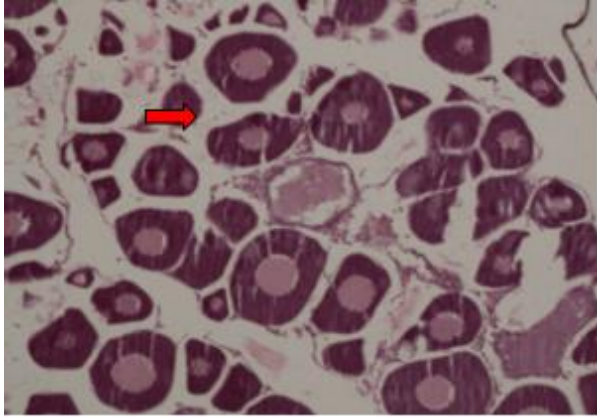


Figure 9: Ovary tissue of infected fishes immature follicle - H&E, X 400

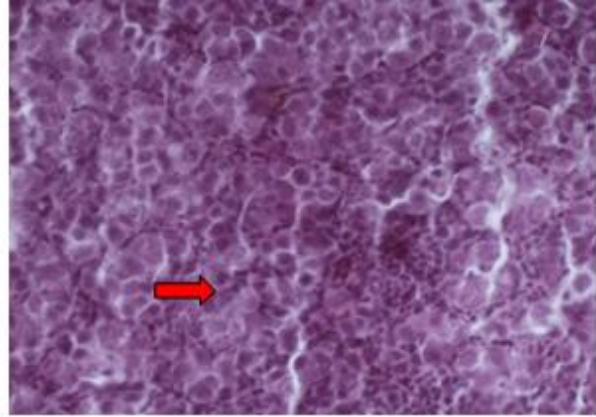


Figure 10: Testicle tissue of infected fishes spermatogonium - H&E, X 400

Winter:

In this season by considering the gonads inactive phase, the samples were mostly like the autumn samples and distinguishing the infected and non-infected fish only from maturation of the gonads tissues would be very difficult, because the sexual cells such as spermatogonium and primary spermatocyte exist in the first stage of maturation in both groups of the fish (Fig.

11), also in infected and non-infected female fish the immature and primary follicles could be distinguished in the ovary tissue (Fig. 12). After this stage the gonads enter the new activity cycle and in non-infected fish, the gonads maturation reaches the final stage and leads to spermatozoid and ovum production in the reproductive season.

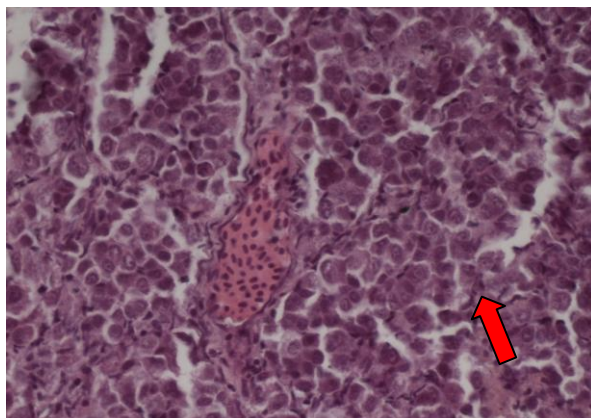


Figure 11: Testicle tissue of infected fishes secondary spermatocytes - H&E, X 400

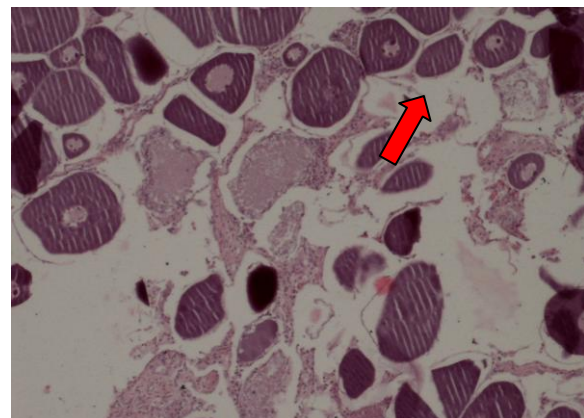


Figure 12: Ovary tissue of infected fishes immature follicle - H&E, X 400

In the seasonal microscopic studies, in addition to the gonads' maturation stages, various pathological changes were seen in

most of the fish gonads which are as follows.

Ovaries:

Abnormal degenerative changes like atretic oocytes and necroses of the sexual cells were seen. The infiltration of inflammatory cells into the ovary capsule

and melano-macrophage centers could be observed. In addition, in the infected fish the ovary capsule did not have its natural resistance and thickness and it was wrinkled (Fig. 13).

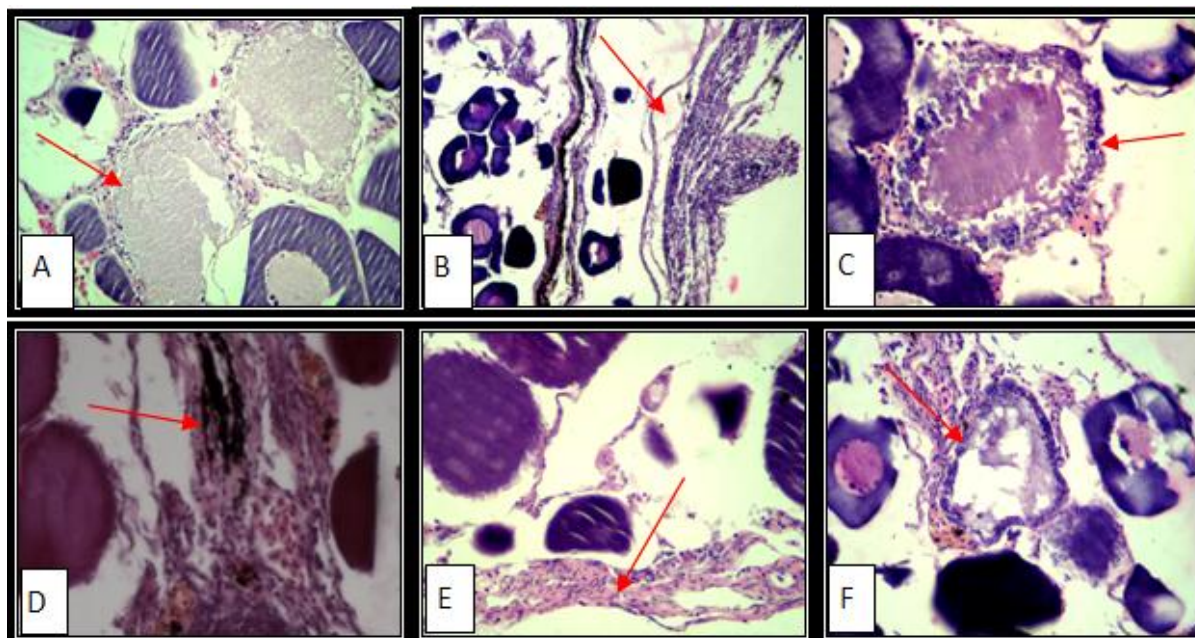


Figure 13 (A-F): Ovary tissue of infected fishes - H & E, X 400 - Atresia and necrosis were seen in oocyte (A) and (C) - capsule of ovary shrink and separated (B) - melano-macrophage center was seen (D) - inflammation and fibrosis were seen (E) - hemorrhage and necrosis were seen in follicles (F).

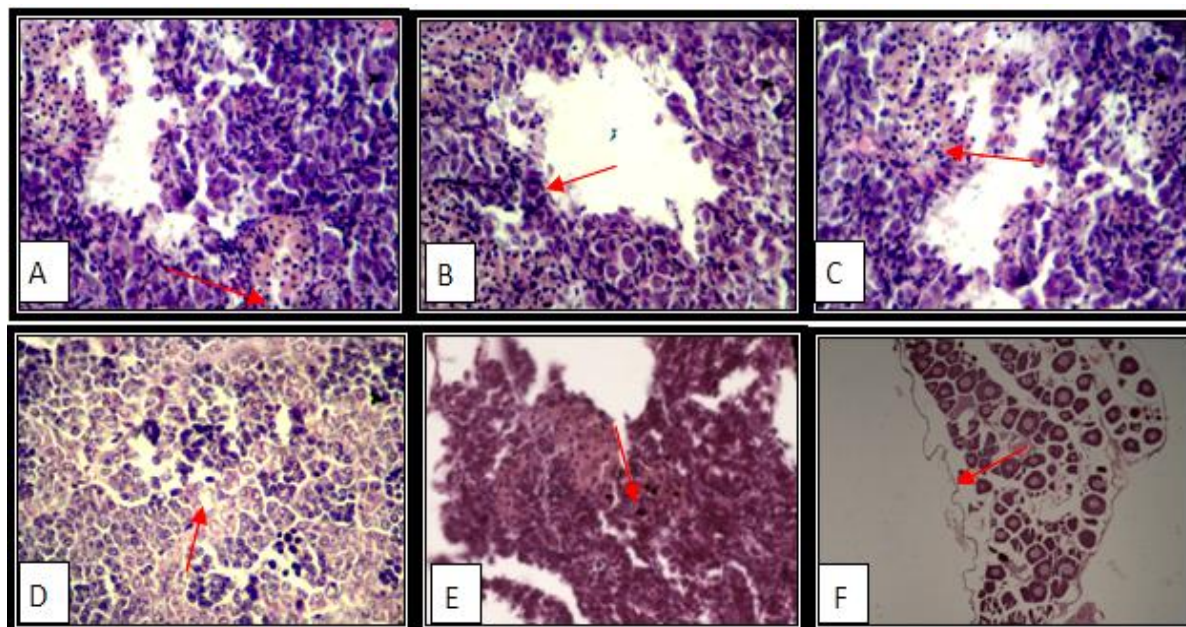


Figure 14 (A-F): Testicle tissue of infected fishes - H & E, X 400 - hemorrhage and inflammation (A) and (C) - necrosis and abnormal tissue were seen (B) - melano-macrophage center was seen (E) and (D) - capsule of testicle shrink and separated (F).

Testicles:

Necrosis and gonads tissue destruction, diffused hemorrhage and creation of empty space under the gonads capsule (which was the sign of gonads atrophy), aggregation of inflammatory cells and observing melano-macrophage centers are pathological changes in the infected fish (Fig.14).

Discussion

According to previous studies, Ligulosis prevalence in Germany's water resources has been reported about 80% of Bream, which showed the high infection possibility in cultivated and wild aquatic animals (Carter et al., 2005). According to (Jalali and Barzegar, 2006) the maximum infection (28.91%) has been reported in Zerivar Lake of Kurdistan, Iran which shows the importance of this parasite outbreak. Based on the results of this research, in all infected fish compared to non-infected ones (with the same age), delay in gonads maturation stages, especially in the spawning season, was seen and in both groups there was a meaningful relationship between the male and female fish gonads maturation stages. If other conditions such as age, nutrition, temperature, genetics, and so on was the same for all of the studied fish, the infection with *Ligula intestinalis*, could be a reason of gonads immaturation through different ways. According to Arme (1968), this delay is caused by the parasite's secretion and anti-gonadotropin substances. The taken samples in spring season, showed immaturation in the infected male fish gonads tissues, which primary and secondary spermatogonium cells could be seen, and in the ovary

tissues of the infected female fish, immature follicles could be observed. Contrarily, this was not seen in the non-infected fish gonads tissues and because of being in the reproduction season, spermatozoid in their gonads tissue and complete matured follicles in their ovary tissues could be seen typically. Other studies confirm this completely (Arme, 1968; Achim et al., 2008). In the summer, although the spawning season was coming to an end and the gonads were returning to the primary stage, the matured sexual cells in some of the non-infected fish could still be seen, while in the infected fish the gonads were completely immature. In the fall and winter, although the gonads have entered into the inactive phase, distinguishing between the infected and non-infected fish gonads tissues becomes more difficult and sometimes impossible; it was because of the sexual cells' resemblance in the first stages of gonads maturation. In all teleost fish, observing atretic follicles and sexual cells' necrosis could be ordinary as a result of environmental conditions and is a pathological change (Pousti and Marvasti, 1999), but in this research because of the same environmental condition in infected and non-infected fish, the effect of the environment was unlikely. The atrophy of oocytes, infiltration of inflammation cells, hemorrhage in the infected fish gonads, melano-macrophage centers, and wrinkling of gonads capsule were some significant points of this research, which have not been considered in previous reports. This status could be a result of the parasite's various effects by producing chemical secretion and the effect of this secretion on

different organs of the fish by considering the fish genetic and the level of their immunity, environmental and nutritional conditions and the parasite metabolism. In addition, the presence of *Ligula* in the fish causes change in their gonads which resulted in hormone disorders (Williams et al., 1998; Carter et al., 2005; Achim et al., 2008). Observing the melano-macrophage centers, which shouldn't naturally be in the gonads tissues, shows an acute or a chronic inflammation process. This event has not been mentioned by (Arme, 1968; Achim, 2008) who did the only pathological studies in this field. The presence of these damages could be the reason of widespread parasite pathogenesis that could be affected by the host's environmental, genetic, and nutritional characteristics. By considering the above mentioned cases about Gheshlagh Dam and its native fish, we can say that *Chalcalburnus mossulensis* is the specific host for *Ligula*. This parasite also infects some of the non-economical fish that have been added accidentally to the Dam (like *Gambusia*). The possibility of the outbreak of this infection in other fish like Common Carp and Silver Carp, which are too sensitive to this parasite and are the economical fish of this dam, is high. The results of this study can be useful in making decisions for reducing the factors that affects the native and cultivated fish stock loss.

Acknowledgments

The authors thank Dr. Samira Bahramian (Islamic Azad University, Sanandaj Branch) for her help and guidance.

References

Achim, T., Sabrina, F., Bernd, S. and Werner, K., 2008. Endocrine disruptive

effects in fish induced by parasites. SETAC Europe Annual Meeting, University of Duisburg/Essen, Department of Applied Zoology. 130, 949-955.

Adeli, A., 2001. Manual of Methods in Fish Biology, first edition, Nashre Olom e Keshavarzi Publication, PP. 11-102

Akmirza, A., 2004. The effect of *Ligula intestinalis* plerocercoid on the growth of bitterling (*Rhodeus amarus*), faculty of aquatic products, Department of aquaculture, Istanbul University, Istanbul, Turkey.

Arme, C., 1968. Effects of the plerocercoid larva of *Ligula intestinalis* on the pituitary gland and gonads of its host. *Biological Bulletin*, 134, (1) 15-25.

Bahre Kazemi, M., Soltani, M., Matinfar, A., Abtahi, B., Pousti, I., Mohagheghi Samarin, A. and Mojazi Amiri, B., 2009. Biochemical and histological studies of over-ripened oocyte in the Caspian brown trout (*Salmo trutta caspius*) to determine biomarkers for egg quality. *Iranian Journal of Fisheries Sciences*, 9(1), 33-48

Carter, V., Pierce, R., Dufour, S., Arme, C. and Hoole, D., 2005. The tapeworm *Ligula intestinalis* inhibits LH expression and puberty in its teleost host, *Rutilus rutilus*, *Journal of Clinical Chemistry* 130, 939-945.

Choudhury, A. and Dick, T. A., 1995. fish diseases and disorders (Vol.1) Protozoan and metazoan infection CABI. Wallingford. Oxon. UK. 8DE.UK, PP: 391-414.

Dubinana, M. N., 1980. Tape worms (Cestoda, Ligulidae of the fauna of the USSR). Amerind publishing co. PVT. LTD. New Delhi, PP 235-239

Eagderi, S., 2002. A histological study on gonadal development of the male and female bulatmai barbell *Barbus capito*, Guldenstadi, A thesis submitted for the degree of M.Sc, Dept. Fisheries and Environmental Sciences, Faculty of Natural Resources

Ergonul, M. B. and Ltindag, A. A., 2005. The effects of *Ligula intestinalis* plerocercoids on the growth features of

- tench, *Tinca tinca*, in Mogan Lake. Department of Biology, Faculty of Science, Ankara University, Ankara, Turkey
- Eslami, A., 1997.** Veterinary Helminthology, Vol., 2 Tehran University Publication, PP.261-266
- Gussev, A. V., 1985.** Metazoan Parasites (in Russian) in Bauer, O.N (ed): Key to the Parasites of fresh water of the USSR. Vol, 3. Nauka, publishers, Moscow, Leningrad. PP.110-115
- Jalali, B., 1998.** Parasites and parasitic diseases of freshwater fishes of Iran, Aquaculture Department Training and Extension Division, Iranian Fisheries Co.(SHILAT), PP.24-55.
- Jalali, B. and Barzegar, M., 2006.** Fish parasites in Zarivar Lake. *Journal of Agriculture Science and Technology*, vol.8, 47-58.
- Jalali, M., Khosravi, M., Rohani Haeri, E., Ghorbanzadeh, A., Parsa Khanegah, A., 2008.** Survey on the prevalence and intensity of Ligulosis caused by *Ligula intestinalis*, L. 1758 in *Chalcalburnus* sp in Zarivar lake and changes in sexual hormones levels in infected fishes. *Iranian Journal of Veterinary Sciences*, NO.26, PP.15-19
- Keivany, Y., 2005.** Biology of Fishes, first edition, Isfahan University of Technology Publication, PP.236-237
- Mokhayer, B., 2002.** Diseases of Cultivated Fishes, Fourth edition, Tehran university publication, PP.416-417
- Mortazavi, J., Pazooki, J. and Javanmard, A., 2004.** Infection by *Ligula intestinalis* and *Butriocephalus akilognati* in two species fish of Sattarkhan dam, *Iranian Fisheries Journal*, NO.14, 13 th year. (In Persian)
- Najafi, Y., 1990.** General Geography of Kordestan province, AmirKabir Publication, PP.44-49
- Navabpour, H., 2000.** Applied statistic and SAS, Vol.1, First edition, Rafe Publication, PP.6-18
- Pousti, E. and Adibmoradi, M., 2003.** Comparative histology and histotechnique, Tehran university publication, PP.518-558
- Pousti, E. and Marvasti, S., 1999.** Atlas of fish histology, Tehran University Publication, PP.187-21
- Raissy, M., Ansari, M., Lashkari, A. and Jalali, B., 2010.** Occurrence of parasites in selected fish species in Gandoman Lagoon, Iran, *Iranian Journal of Fisheries Sciences*, 9(3), 464-471
- Razmi, G. and Naghibi, A., 2000.** Comparative Biology and Morphology in Fish Abdominal Plerocercoid, 1Th. Conference of Aquatic animals health and Disease, Ahwaz-Iran
- Roberts, R. J., 2001.** Fish pathology, Saunders publishers, Toronto, Canada, pp.257-264.
- Sattari, M., Shahsevani, D., Shafei, S.H., 2003.** Ichthyology (Systematic), Haghshenas Publication, PP.198-199
- Sharifrohani, M., 1995.** Diagnostics, Prevention and Therapy of Fish Diseases and Intoxications, first edition, Aquaculture Department Training and Extension Division, Iranian Fisheries Co.(SHILAT), PP.241-255
- Soltani, A., 1998.** Applying of SAS software in Statistical analysis, first edition, Jahad-e-Daneshgahi Publication, PP.43-44
- Williams, M. A., Penlington, C., Kingjudy, A., Hoole, D. and Arme, C., 1998.** *Ligula intestinalis* (cestoda) infection of roach (ciprinidea): immunocytochemical investigations into the salmon and chicken – II type gonadotrophin – releasing hormone (GnRH) systems in host brains. *Acta parasitological*, 43(4) 232-235.